

# Immediate results of Coronary Optical Coherence Tomography use in complex lesions: experience from a center in Mar del Plata

Resultados inmediatos del uso de tomografía de coherencia óptica coronaria en lesiones complejas: experiencia de un centro de Mar del Plata

Rodrigo Bruno<sup>1,2</sup> orcid: [0009\\_0007\\_0041\\_7809](https://orcid.org/0009_0007_0041_7809), Francisco Roca<sup>1</sup>, Sebastián M. Sciarra<sup>1</sup>, Guillermo E. Marchetti<sup>2,3</sup>, Raúl Bretal<sup>1</sup>, Jorge A. M. Iravedra<sup>1,3</sup>

## ABSTRACT

**Objective.** To evaluate the immediate results of optical coherence tomography (OCT) in coronary lesions.

**Material and methods.** This study included 60 consecutive patients who underwent OCT between February 2019 and April 2024.

**Results.** The average age was 65±9.5 years. In general, 88% of the OCTs were scheduled, and 12% were conducted as urgent procedures. The most common reason for performing the OCT was ostial lesion of the left anterior descending artery (21.7%), followed by lesion of the left main coronary artery (LMCA) (20%). Overall, 85% of patients underwent OCT-guided percutaneous transluminal coronary angioplasty (PTCA), while 15% were decided not to go through with PTCA after OCT. PTCA was most frequently performed on the LMCA (33%). The use of OCT prior to revascularization led to a treatment change in 47.3% of cases. In the group of patients who underwent OCT after PTCA with stent implantation, the procedure had to be optimized in 59% of cases. This was due to underexpansion, malapposition, and/or dissection, in 45.5%, 29.5%, and 25% of cases, respectively. Regarding patients who underwent stent implantation, 22.7% of them experienced in-stent tissue protrusion. There were no complications related to the use of OCT.

**Conclusions.** OCT proved to be a useful and safe method, especially in lesions involving the LMCA, in its middle and distal segments, for planning therapeutic management and evaluating its outcome, allowing for the correction of potential stent failure.

**Keywords:** optical coherence tomography, OCT, coronary angioplasty, stent, underexpansion, malapposition, dissection, tissue protrusion.

## RESUMEN

**Objetivo.** Evaluar los resultados inmediatos de la tomografía de coherencia óptica (OCT) coronaria.

**Material y métodos.** Entre febrero de 2019 y abril de 2024 se incluyeron 60 pacientes en forma consecutiva a los cuales se les realizó OCT.

**Resultados.** El promedio de edad fue de 65 años ±9,5. El 88% de las OCT fueron programadas y 12% de urgencia. El motivo de realización de la OCT más frecuente fue por lesión ostial de arteria descendente anterior (21,7%), seguido de lesión del tronco de arteria coronaria izquierda (TCI) (20%). Al 85% se les realizó angioplastia coronaria (PTCA) guiada por OCT, mientras que al 15% luego de realizada la OCT, se decidió no continuar con PTCA. La PTCA más frecuentemente realizada fue del TCI (33%). Con la utilización de la OCT pre revascularización se generó un cambio de conducta en el 47,3%. En el grupo de pacientes a los cuales se realizó OCT post-PTCA con implante de stent, se debió optimizar el procedimiento en el 59% de los casos. Esto fue por subexpansión, mala aposición y/o disección, siendo la frecuencia de estas del 45,5%, 29,5% y 25%, respectivamente. El 22,7% de los pacientes con stents implantados presentaron protrusión de tejido intrastent. No hubo complicaciones relacionadas con la utilización de OCT.

**Conclusiones.** La OCT resultó ser un método útil y seguro, principalmente en lesiones que comprometen el TCI, en sus segmentos medio y distal, para planificar la conducta terapéutica y evaluar el resultado de la misma, pudiendo corregir las potenciales fallas del stent.

**Palabras clave:** tomografía de coherencia óptica, OCT, angioplastia coronaria, stent, subexpansión, mala aposición, disección, protrusión de tejido.

*Revista Argentina de Cardioangiología Intervencionista* 2024;15(4):192-196. <https://doi.org/10.30567/RACI/202404/0192-0196>

## INTRODUCTION

Angiography is the standard method for assessing the coronary tree and guiding coronary angioplasty, but it has limitations, as it does not allow for the visualization of the vessel wall, exact diameters, plaque characteristics, or a detailed view of stenting results. It displays a complex three-dimensional structure in two dimensions<sup>1</sup>. These limitations have driven the develop-

ment of new intravascular imaging diagnostic techniques<sup>2</sup>. Optical coherence tomography (OCT) is an interferometric optical tomographic imaging technique that offers millimeter penetration (approximately 2-3 mm into tissue), similar to conventional biopsy thickness, and axial and lateral resolution on a micrometric scale<sup>2-3</sup>. It is an alternative to intravascular ultrasound (IVUS) for obtaining intravascular images. It measures the intensity of reflected infrared light instead of using the image generated by ultrasound<sup>3</sup>. The higher resolution of OCT compared to other intravascular diagnostic techniques allows for accurate measurement of vessel diameter and luminal area for correct stent selection. Additionally, this technique has more sensibility for detecting dissections, stent malapposition, or minimal plaque prolapses when compared to IVUS<sup>2</sup>. However, its penetration into the vascular wall is limited, so visualization of structures that are far from the lumen (near the adventitia) is compromised when there is a significant amount of atherosclerotic plaque<sup>4</sup>.

1. Department of Interventional Cardiology. Clínica 25 de Mayo. Mar del Plata. Buenos Aires. Argentina

2. Department of Interventional Cardiology. Clínica Privada del Sol. Villa Gesell, Buenos Aires. Argentina

3. Hospital Emilio Ferreyra. Department of Interventional Cardiology. Necochea. Buenos Aires. Argentina

✉ Corresponding author: Rodrigo Bruno. Clínica 25 de Mayo, 25 de Mayo 3542, B7600GWY Mar del Plata, Buenos Aires, Argentina. Fax: 0223 47-43461. [rodribruno@hotmail.com](mailto:rodribruno@hotmail.com).

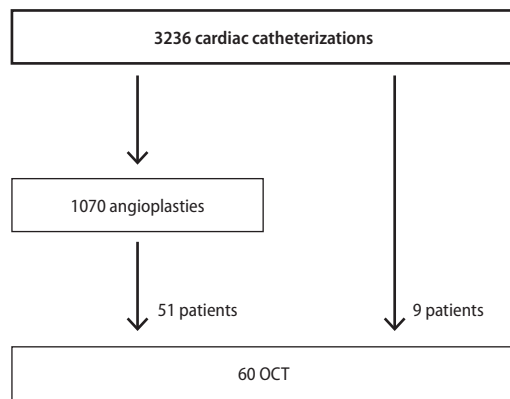
Conflicts of interest: No conflicts of interest whatsoever

Received: 04/10/2024 | Accepted: 27/01/2025

**TABLE 1.** Reason for OCT.

	Frecuencia	Porcentaje
Ostial lesion in the anterior descending artery	13	21.67%
Lesion in the left main coronary artery	12	20.00%
Ostial lesion in the circumflex artery	7	11.67%
In-stent restenosis	7	11.67%
Bifurcation lesion not in trunk	7	11.67%
Probable dissection	6	10.00%
STEACS	5	8.33%
Balloon underexpansion	1	1.67%
Angiographically-assessed severely calcified lesion	1	1.67%
Vessel sizing	1	1.67%
Total	60	100.00%

The reason for OCT is described by frequency.



**Figure 1.** Flow diagram of the procedures performed between February 2019 and April 2024.

**Objective**

To evaluate the immediate results of OCT in a healthcare center in the city of Mar del Plata.

**MATERIAL AND METHODS**

This is an observational, descriptive, and prospective study. Out of a total of 1070 angioplasties conducted between February 2019 and April 2024, researchers included 60 consecutive patients (5.6%) who underwent endovascular imaging acquisition by OCT (Figure 1). Once a decision was made to perform the procedure, patients were invited to participate in the study and asked to sign an informed consent form. For image acquisition, a Dragonfly Optis (Abbott) optical fiber catheter was used. All patients were on dual antiplatelet therapy at the time of the study and were administered a dose of at least 70 IU/kg of sodium heparin by means of an intra-arterial bolus. In cases where there were no contraindications, intracoronary nitroglycerin was also administered.

**Definitions**

Malapposition: separation of the stent struts from the vessel wall greater >0.4 mm and with a length >1 mm.

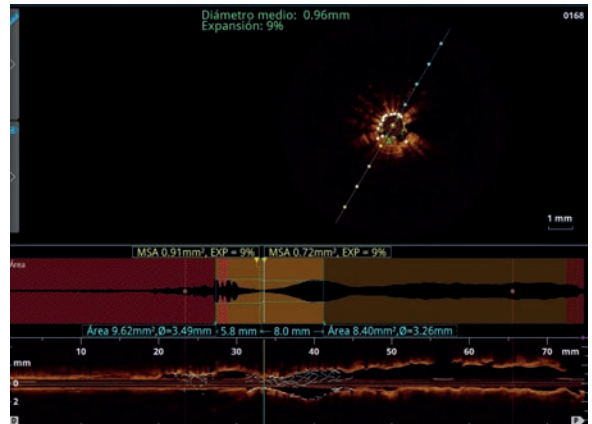
Underexpansion: when the ratio between the minimum stent luminal area and the average proximal and distal luminal area multiplied by 100 is <80%.

Edge dissection: disruption of the arterial lumen surface with clear separation from the vessel wall or underlying plaque within 5 mm of one end of the stent, observed in at least two consecutive images. It was considered significant if it

**TABLE 2.** Tipo de angioplastia.

	Frequency	Percentage
Left main coronary artery	20	33.33%
Other	10	16.67%
None	9	15.00%
Bifurcation lesion not in trunk	7	11.67%
In-stent restenosis	6	10.00%
Emergency PTCA	5	8.33%
Coronary dissection	3	5.00%
Total	60	100.00%

Se describe por orden de frecuencia el tipo de angioplastia coronaria realizada guiada por OCT.



**Figure 2.** Extreme case of underexpansion (9%) of multiple layers of previously implanted stents.

compromised more than 60° of the circumference, was deep (involving the media or adventitia), or had a length >2 mm. Tissue protrusion: extrusion of tissue inside the stent.

**Statistical analysis**

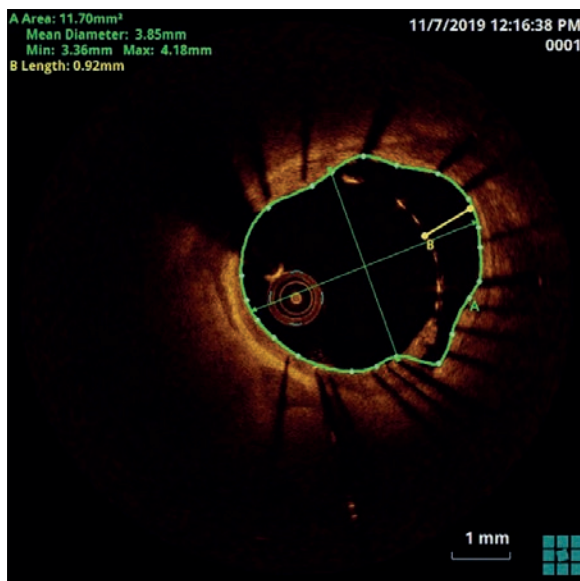All values are expressed as mean and standard deviation (for continuous variables) or as count and percentage (for categorical variables). Data analysis was conducted using the EPI Info 7.2.6.0 biostatistics software.

**RESULTS**

During the study period, there were 60 patients included. Their average age was 65 years (standard deviation [SD] 9.5428; range: 44-86 years), and 83.3% of subjects were men. Regarding the procedures, 88% had been scheduled beforehand while 12% were conducted as urgent.

Table 1 shows the reasons for performing OCT. The most common was ostial lesion in the anterior descending artery (21.7%), lesion in the left main coronary artery (LMCA, 20%), ostial lesion in the circumflex artery (11.7%), in-stent restenosis (11.7%), and bifurcation lesions that did not involve the left main coronary artery (11.7%).

In 85% (51/60 patients) of cases, patients underwent OCT-guided percutaneous transluminal coronary angioplasty (PTCA). Of them, 50 patients underwent stenting while one had a drug-eluting balloon implanted. Additionally, in 15% (9/60 patients) of cases a decision was made not to go forward with PTCA after OCT. Table 2 shows the type of procedure performed. The most frequent was in the left main coronary artery (33%), followed by bifurcation angioplasty not involving the LMCA (11.7%).



**Figure 3.** Significant stent malapposition at the proximal third of the left anterior descending artery, with a 0.92-mm strut separation.

In the PTCA group, 11.76% (6/51 patients) of subjects underwent pre-PTCA OCT. Then, 43.14% (22/51 patients) of subjects underwent post-PTCA OCT, and 45% (23/51 patients) of subjects underwent both pre- and post-PTCA OCT. Of the 38 patients who underwent OCT before revascularization, there was a change in approach in 47.3% (18 patients) of cases, either because a decision was made not to proceed with endovascular revascularization (9 patients) or because the stenting strategy was modified.

In the group of patients who underwent OCT after PTCA with stent implantation, the underexpansion rate was 45.5% (20 of 44 patients who underwent stenting), and the malapposition rate was 29.55% (13 of 44 patients). OCT-guided post-dilation was performed in 48% (21 of 44 patients) due to underexpansion and/or malapposition. **Figures 2 and 3** show a case of stent underexpansion and stent malapposition, respectively.

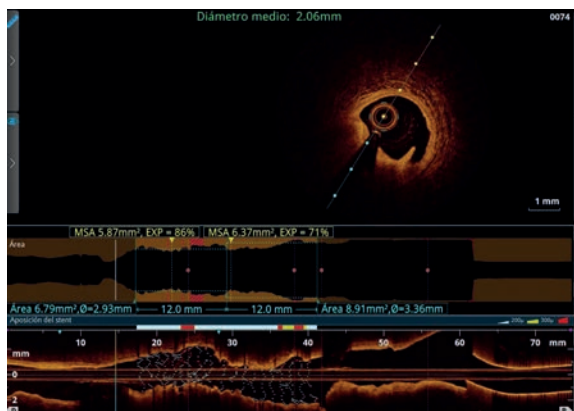
There were 14 detected coronary dissections (31.8% of patients). In 92% (13 patients) of cases, that occurred after stent implantation; in 78% of cases, the dissection was significant (11 patients) and required correction with another stent. In other words, 25% (11 of 44 patients) of patients with implanted stents required correction for a significant dissection. **Figure 4** shows a case of a significant coronary dissection.

Tissue protrusion was observed in 22.7% of the implanted stents (10 of 44 patients). See **Figure 5**.

In one patient who underwent PTCA for STEMI, there was an intracoronary thrombus attached to the stent (**Figure 6**). We can conclude that, in patients who underwent OCT after PTCA with stent implantation, the procedure had to be optimized in 59% of the cases (26 of 44 patients), by means of post-dilation and/or new stent implantation to correct coronary dissection, underexpansion, or malapposition. There was no need to correct the tissue protrusion, as its size was small. There were no complications related to the use of OCT.

## DISCUSSION

Of the total number of angioplasties performed, only a small percentage used OCT (5.6%), due to lack of availability of



**Figure 4.** Significant coronary dissection distal to an implanted stent.

the method mainly driven by its high cost. While in developed countries, such as the US, the rate of use of intravascular imaging remains low, a report places it at 16.6%<sup>5</sup>.

Procedures were most frequently scheduled, although this technique was also used and proved useful in urgent situations.

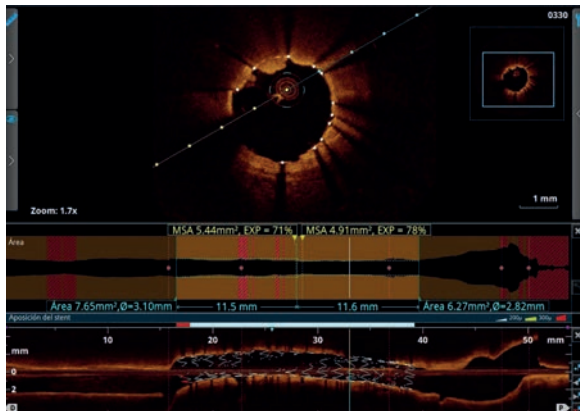
Regarding the reason for performing OCT, most cases were due to lesions in the left main coronary artery lesions or involving the trunk (ostial lesions in the anterior descending or circumflex artery), reaching 53%. European cardiology guidelines recommend intravascular imaging for complex coronary lesions, particularly for left main coronary artery lesions, true bifurcation lesions, and long lesions, with an IA level of evidence<sup>6</sup>. It should be noted that OCT is not useful for the assessment of aorto-ostial lesions. In these cases, there is an advantage with IVUS<sup>7</sup>. The method was used in all cases to assess left main coronary artery lesions that involved the middle third or bifurcation.

The importance of pre-PTCA assessment with OCT was evidenced in the ILUMIEN I study, where pre-PTCA images resulted in a change in strategy in 57% of the cases<sup>8</sup>. There was a strategy change after pre-revascularization OCT in 47.3% of cases, either because a decision was made not to continue with PTCA based on the findings or due to a change in strategy regarding stent implantation.

Underexpansion is the greatest predictor of stent failure<sup>9</sup>, as it is associated with stent thrombosis and restenosis<sup>10,11</sup>. In the CLI-OPCI study, there was a 31% underexpansion rate, with an increase in major cardiovascular events (MACE) during follow-up<sup>12</sup>. We detected a high percentage of sub-expanded stents (45.5%) using OCT. Had it not been for this method, if we had only used angiographic assessment, underexpansion would have gone unnoticed, potentially increasing the rate of MACE.

The observed stent malapposition rate was close to 30%, lower than the 41% found in the ILUMIEN III study<sup>13</sup>. Currently, the impact of stent malapposition on future events remains unclear<sup>9</sup>.

The incidence of coronary edge dissection was 31.8%, similar to the 39.1% found in the study by Daniel Chamié *et al.*<sup>14</sup>. There is a correlation between large dissections and stent thrombosis<sup>14,15</sup>. Average large dissections are characterized by their depth, lateral extension (>60°), and length (>2 mm)<sup>9</sup>. Dissections >200 μm from the distal (not proximal) end of the stent are associated with higher rates of MACE<sup>15</sup>. The widespread consensus is that small dissections at the edges of the stent, which are very frequently detected



**Figure 5.** Tissue protrusion through the stent struts between the 11 o'clock and 12 o'clock positions.

with OCT, should not be treated<sup>4</sup>. In our registry, 25% of patients who underwent stenting and post-procedure OCT had a significant dissection that required intervention. In other words, we can say that, of all dissections, 78% required stenting, in contrast to Daniel Chamie's study where only 22.6% required a stent<sup>14</sup>.

Tissue protrusion was a frequent event, reaching almost 23%. Mild tissue protrusion within the stent (thrombus or plaque), as found in our registry, does not require specific treatment<sup>4</sup>.

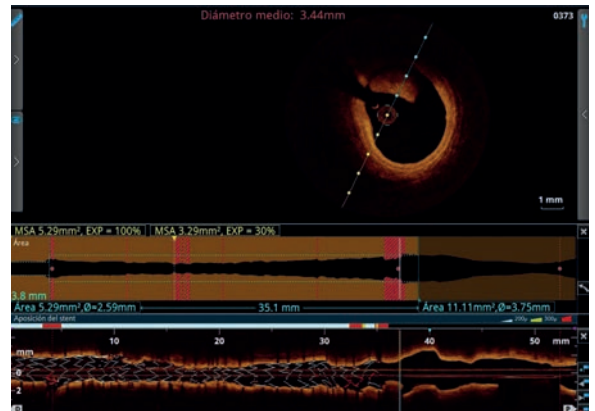
Regarding the use of post-PTCA OCT, it allowed us to optimize the stent or correct anomalies—either due to underexpansion, significant malapposition, or post-stent implantation dissection—in 59% of patients. Multiple studies show that OCT-guided stent optimization is performed in between 27% and 52.2% of lesions, mainly driven, as in our study, by malapposition, underexpansion, or edge dissection<sup>1</sup>. In the ILUMIEN I study, the post-PTCA strategy change rate was 27%.

All of the above leads us to conclude that OCT was useful both before and after PTCA, as it allowed us to choose a more suitable strategy and correct anomalies that were not detected by angiography alone.

There is evidence showing that OCT was superior to IVUS in detecting plaque rupture or thrombus, tissue protrusion, stent edge dissection, and malapposition<sup>16</sup>.

It has been shown that OCT is safe in routine clinical practice<sup>17</sup>, with a low rate of major complications, such as ventricular fibrillation (1.1%), air embolism (0.6%), or coronary dissection (0.2%)<sup>2</sup>. In our registry, we did not observe complications related to its use, which confirmed it to be, in our experience, a very safe method for the angioplasty planning and evaluation.

Due to its high cost, using endovascular imaging acquisition in all PTCA procedures is not feasible. However, it is very



**Figure 6.** Intracoronary thrombus, with features of white thrombus due to the presence of low lumen attenuation, at the proximal end of a stent.

important to clearly determine which cases should include it, as it provides valuable information with prognostic implications superior to the use of angiography only.

### Limitations

This is an observational study. Since it was conducted at a single center, results may not be generalizable to other populations. It assesses immediate outcomes; its lack of follow-up limits the analysis of long-term results, particularly regarding major adverse cardiovascular events (MACE). Additionally, due to the high cost of the assessed method, the number of patients was limited in relation to the total number of PTCA procedures.

### CONCLUSIONS

OCT proved to be a useful and safe method, especially in complex lesions involving the LMCA, in its middle and distal segments, for planning therapeutic management and evaluating its outcome, allowing for the correction of potential stent failure.

### SUMMARY OF KEY POINTS

- OCT is an intravascular imaging method with very low risk for complications, which allows for precise determination of anatomical features that may not be visible on angiography.
- It is highly useful for both planning and optimizing percutaneous interventions.
- In many cases, it leads to changes in the approach planned based solely on angiographic evaluation.

We thank Dr. Guillermo Migliaro for his advice and collaboration in drafting this article.

### REFERENCES

1. Timo T.M, Oosterveer, Sander M. van der Meer, Roderick W. C. Scherptong. Optical Coherence Tomography: Current Applications for the Assessment of Coronary Artery Disease and Guidance of Percutaneous Coronary Interventions. *Cardiol Ther* (2020) 9:307-321.
2. Herrero-Garibi J, Cruz-González I, Parejo-Díaz P, et al. Tomografía de coherencia óptica: situación actual en el diagnóstico intravascular. *Rev Esp Cardiol*. 2010;63(8):951-62.
3. Patel NA, Stamper DL, Brezinski ME. Review of the Ability of Optical Coherence Tomography to Characterize Plaque, Including a Comparison with Intravascular Ultrasound. *Cardiovasc Intervent Radiol* (2005) 28:1-9.
4. Alfonso F, Rivero F. Optimización del implante de stents guiado por tomografía de coherencia óptica: ver para creer. *Rev Esp Cardiol*. 2015;68(3):175-178.

5. Ryan D Madder, Milan Seth, Devraj Sukul, et al. Rates of Intracoronary Imaging Optimization in Contemporary Percutaneous Coronary Intervention: A Report From the BMC2 Registry. *Cardiovasc Interv.* 2022 Oct;15(10):e012182.
6. 2024 - ESC Guidelines for the management of chronic coronary syndromes. *European Heart Journal* (2024) 45, 3415–3537.
7. Vinayak Nagaraja, Ankur Kalra, Rishi Puri. When to use intravascular ultrasound or optical coherence tomography during percutaneous coronary intervention?. *Cardiovasc Diagn Ther* 2020;10(5):1429-1444.
8. Wijns W, Shite J, Jones MR, et al. Optical coherence tomography imaging during percutaneous coronary intervention impacts physician decision-making: ILUMIEN I study. *Eur Heart J* 2015;36:3346–3355.
9. Lorenz Räber, Gary S. Mintz, Konstantinos C. Koskinas, et al. Clinical use of intracoronary imaging. Part 1: guidance and optimization of coronary interventions. An expert consensus document of the European Association of Percutaneous Cardiovascular Interventions. *European Heart Journal* (2018) 00, 1–20.
10. Kenichi Fujii, MD, Stéphane G. Carlier, MD, PHD, Gary S. Mintz, MD, et al. Stent underexpansion and residual reference segment stenosis are related to stent thrombosis after sirolimus-eluting stent implantation. An intravascular ultrasound study. *J Am Coll Cardiol* 2005;45:995–8.
11. Xuebo Liu, Hiroshi Doi, Akiko Maehara, et al. A Volumetric Intravascular Ultrasound Comparison of Early Drug-Eluting Stent Thrombosis Versus Restenosis. *J Am Coll Cardiol Intv* 2009;2:428–34.
12. Francesco Prati, Enrico Romagnoli, Francesco Burzotta, et al. Clinical Impact of OCT Findings During PCI. The CLI-OPCI II Study. *J Am Coll Cardiol Img* 2015;8:1297–305.
13. Ziad A Ali, Akiko Maehara, Philippe Généreux, et al. Optical coherence tomography compared with intravascular ultrasound and with angiography to guide coronary stent implantation (ILUMIEN III: OPTIMIZE PCI): a randomised controlled trial. *Lancet.* 2016 Nov 26;388(10060):2618-2628.
14. Daniel Chamíé, Hiram G. Bezerra, Guilherme F. Attizzani, et al. Incidence, Predictors, Morphological Characteristics, and Clinical Outcomes of Stent Edge Dissections Detected by Optical Coherence Tomography. *JACC Cardiovasc Interv.* 2013 Aug;6(8):800-13.
15. Cutlip DE, Baim DS, Ho KK, et al. Stent thrombosis in the modern era: a pooled analysis of multicenter coronary stent clinical trials. *Circulation* 2001;103:1967–71.
16. Marcos Garcia-Guimaraes, Paula Antuña, Francisco De la Cuerda, et al. High-Definition IVUS Versus OCT to Assess Coronary Artery Disease and Results of Stent Implantation. *JACC Cardiovasc Imaging* 2020;13:519-21.
17. Barlis P, Gonzalo N, Di Mario C, et al. A multicentre evaluation of the safety of intracoronary optical coherence tomography. *EuroIntervention.* 2009;5:90-5.